

Hepatoprotective Effect of Tocotrienol Rich Fraction from Palm Fatty Acid Distillate on Liver Peroxidation Induced by Thermally Oxidized Frying Oil

Teti Estiasih^{1*}, Jublina Bakoil², Kgs. Ahmadi³, Moch. Nur Cholis, Elok Zubaidah¹, Grace Martanty Paska¹, Huda Oktafa⁴

¹Department of Food Science and Technology, Faculty of Agricultural Technology, Brawijaya University, Jl. Veteran, Malang, Indonesia 65145

²Department of Agricultural Product Technology, Faculty of Agriculture, Tribuana University, Jl. Sukarna, Kalabahi, Nusa Tenggara Timur and Master Degree of Agricultural Product Technology, Faculty of Agricultural Technology, Brawijaya University, Jl. Veteran – Malang, Indonesia 65145

³Department of Agroindustry Technology, Faculty of Agriculture, Tribhuwana Tungadewi University, Jl. Telaga Warna, Tlogomas, Malang, Indonesia 65144

⁴Master Degree of Agricultural Product Technology, Faculty of Agricultural Technology, Brawijaya University, Jl. Veteran – Malang, Indonesia 65145

*Corres.author: teties@yahoo.co.id and teties@ub.ac.id

Abstract: Tocotrienol rich fraction (TRF) from palm fatty acid distillate (PFAD) was examined its ability to protect liver from lipid peroxidation induced by thermally oxidized frying oil. Six groups of rats were treated by TRF 0, 25, 50, and 75 mg/kg bw/day and commercial vitamin E at dose of 75 mg/kg bw/day. The normal rats was used as a control group. Hepatoprotective effect of TRF was measured by liver malondialdehyde (MDA) level, superoxide dismutase activity, catalase activity, and hepar histopathology. The results showed that TRF from PFAD was effective antioxidant to protect liver from peroxidation, indicated by decreasing liver MDA level, increasing liver SOD activity, and increasing liver catalase activity, as well as impairment in hepatocytes after TRF force feeding. The effective dose of TRF was 50 mg/kg bw/day. At higher dose (75 mg/kg bw/day) TRF caused highest average number of hepatocellular degeneration and revealed more pronounce oxidative damage than TRF dose of 50 mg/kg bw/day. At lower dose (25 mg/kg bw/day) TRF was not effective to prevent liver from lipid peroxidation. TRF was more effective as hepatoprotector than commercial vitamin E.
Keywords: tocotrienol, hepatoprotector, peroxidation, MDA, SOD, catalase, histopathology.

Introduction

Lipid oxidation products in the forms of free radicals are usually related to some diseases^{1,2}. Oxidative degeneration almost has a role on disease pathology such as atherosclerosis, ischaemic heart disease, and traumatic brain damage. Oxidative stress also acts in protein and DNA damages^{3,4,5} that obstructs cell main structure and functions and contributes to some degenerative diseases such as cancer and premature aging^{6,7}. Unconsciously, human being often consume lipid oxidation products from oxidized foods.

Basically, human body has antioxidant defense mechanism such as superoxide dismutase (SOD), glutathion peroxidase, and catalase, as well as non enzymatic antioxidants such as vitamin E and vitamin C^{8,9,10}. Enzymes and antioxidants have a role to reduce free radicals that produced naturally from human body. In oxidative stress condition, human body needs additional antioxidant exogeneously from foods.

One of the vitamins that has an important role in inhibiting oxidative stress is vitamin E^{4, 11-15}. The most consumed vitamin E that serves as antioxidant is tocopherol. Alfa tocopherol has been produced commercially as food supplement. Other types of vitamin E that reveal better antioxidant activity in the body are tocotrienols.

One of the sources of tocotrienols that has not been explored extensively is palm fatty acid distillate (PFAD). Physical palm oil refining to obtain edible palm oil includes degumming, bleaching, and dedorization. Dedorization step produces a by-product that is known as PFAD. The main component of PFAD is free fatty acids, and other minor components are oxidation products and health beneficial bioactive compounds that comprises of tocopherol, tocotrienols, phytosterols, and squalene. According to Liu *et al*¹⁶, PFAD contains tocopherol and tocotrienols 0,7-1%. It is well known that palm oil is a potential source of tocotrienols compared to other sources such as rice bran¹⁷, grape seed¹², red rice bran¹⁸, olive oil¹⁹, and sea buckthorn berry²⁰. Palm oil is different to other vegetable oils because the main vitamin E in crude palm oil is tocotrienols (83%) and the remaining is tocopherol (17%)²¹. So far, the sources of tocotrienols are still limited, therefore PFAD utilization as a source of tocotrienols is important to explore.

The study of Hakim²² and Hanani²³ showed that tocotrienols are able to be separated from PFAD by low temperature solvent crystallization. This technique is simple and able to simultaneously produced liquid soap and tocotrienol rich fraction (TRF). The exellency of tocotrienols compared to tocopherol is higher ability to inhibit liver cell microsomal and mitochondrial peroxidation, as well as to reduce oxidation of dioleoylphosphatidylcholine liposomes better than tocopherols^{24, 25}. Liver peroxidation is very dangerous to hepatic cell because oxidative stress and lipid peroxidation have been related to several types of liver injuries^{26, 27}.

This study was objected to assess the ability of TRF from PFAD in protecting liver from peroxidation that induced by thermally oxidized frying oil. In this study, hepatoprotective effect of TRF was measured by liver malondialdehyde (MDA) level, superoxide dismutase activity, catalase activity, and hepar histopathology.

Materials And Methods

Materials

PFAD was kindly obtained from a palm oil refinery, PT Salim Ivomas Pratama, Surabaya. Chemical reagents used to separate TRF from PFAD was KOH (technical grade), ethanol (technical grade), ascorbic acid, hexane (technical grade) (Bratachem). Reagents used for analysis was H₂O₂, NBT (Nitro Blue Tetrazolium), EDTA, SOD, akuabides, Na-thiol, MDA, metaphosphoric acid, NaCl, sodium nitroprusside, DTNB, paraformaldehyde, PBS, paraffin, hematoxyllin, eosin, benzene, methanol, BaCl₂, FeSO₄, H₂O₂, ammonium chloride, BaSO₄ (Merck), and feed from Comfeed PARS that mixed with wheat flour, thermally oxidized frying oil with peroxide value of 102.3 meq/kg, methanol (HPLC grade), α tocopherol (Nacalai, Japan), α , β , δ , γ tocotrienols (Santa Cruz, USA), NaOH (Merck), filter paper, Whatman No. 1 filter paper, and commercial vitamin E supplement.

Tocotrienol Rich Fraction Preparation

Tocotrienol rich fraction (TRF) was prepared according to the method of Ahmadi²⁸. Analysis of tocopherols and tocotrienols in TRF was referred to method of Ball²⁹ by using HPLC (Shimadzu LC20AT) with VP-ODS column (4.6 mm × 25 mm), detector UV (SPD 20A). TRF were diluted in methanol at concentration of 1000 ppm and this solution was sieved by milipore 0.4 μm. The solution was injected in the volume of 100 μL. The mobile phase was methanol:water 95:5 and the flowrate was 1 ml/min. Each standard of vitamin E was injected into HPLC column separately for identification and quantification.

Hepatoprotective Effect Assay

Male Sprague Dawley rats were adapted into laboratory environment for a week and then divided into 6 groups that each group comprised of 4 rats. Lipid peroxidation was induced by force feeding 2 mL/rats thermally oxidized frying oil with peroxide value of 102 meq/kg everyday during adaptation and experiment. Each groups of rats were force fed by TRF in the doses of 0, 25, 50, and 75 mg/kg bw/day. In comparison, commercial vitamin E was force fed in the dose of 75 mg/kg bw/day into peroxidation induced rats and a group of normal rats was used as a control. During adaptation and experiment, rats were fed by standard feed of Comfeed PARS that mixed with wheat flour³⁰, and this feed had composition of moisture 12%, protein 11%, fat 4%, fiber 7%, as 8%, Ca 1,1%, phosphor 0,9%, and antibiotic.

At the end of experiment (day 28th), the rats were anaesthetized and the liver was taken out to examine for analysis of MDA level, SOD, and catalase activities, and histopathology. Data was analyzed by analysis of variance and least significant difference to know the difference among treatments at level of 0.05. This study protocol had been approved for ethical clearance No. 87-KEP-UB from Animal Care and Use Committee, Brawijaya University.

Liver Malonaldehyde (MDA) Level Analysis³¹

Homogenized liver tissue (400 μL) was mixed with TCA 10% and incubated for 15 min at 4°C, and after that the mixture was centrifuged at 200 g for 15 min at 4°C. Free protein supernatant of 1 μL was added by 1 ml of fresh TBA reagent, homogenized and incubated in the water bath with temperature of 60°C for 1 h. The absorbance of the mixture was measured at 532 nm and lipid peroxidation was expressed as ng MDA/ml supernatant.

Liver SOD Activity Assay³²

SOD activity was measured as autooxidation of hydroxylamine at pH 10.2 followed by NBT reduction, and the resulted nitrite in the existence of EDTA was detected colorimetrically. One unit of SOD activity meant as the amount of protein in the 100 μl of 10% serum required to inhibit as much as 50% of 24 mM NBT reduction and expressed as unit/ml.

Catalase Activity Assay³²

Catalase activity was measured by determining decomposition of H₂O₂ at 240 nm in phosphate buffer. One unit of catalase meant the amount required for 1 mM H₂O₂/min/mg protein reduction at 37°C. Catalase activity was expressed as μmol H₂O₂/ml supernatant.

Liver Histopathological Analysis³³

Histopathological examination of liver was referred to method of Sun *et al.*³³. Each rat was anesthetized with chloroform. A piece of liver tissue (±1 g) was dissected from the central lobe and immersed in 4% paraformaldehyde in PBS. The tissue was fixed at room temperature for 48 h before being embedded in paraffin. Tissue sections (6 mm) were cut on a microtome, and slides were delipidated and rehydrated by passing through graded alcohols. Specimens were stained with hematoxylin and counterstained with eosin using standard protocols. The slides were mounted with xylene and covered with a cover slip. Histologic assessment of the liver sections was carried out independently by one expert. A grading scale of 1–5 was used with 1 indicating no abnormal histologic structure observed and 5 indicating the greatest degree of altered histologic structure present. Abnormalities were based primarily upon the presence of altered general hepatic lobule

architecture and the presence and extent of steatosis within the liver acinus. The following grading scale was used for each of the treatment groups:

1. Hepatic lobules are observed, demonstrating a radial arrangement of hepatic plates from the central vein with nominal branching. Sinusoids are regular between the hepatic plates. Hepatocytes show centrally located nuclei and no evidence of steatosis.
2. Hepatic lobules are observed, but the radial arrangement of the hepatic plates from the central vein is less distinct. Branching of the hepatic plates is more apparent and sinusoids may show dilation. Hepatocytes stained lightly with large central nuclei. No evidence of steatosis.
3. Hepatic lobules are apparent, but the radial arrangement of hepatic plates from the central vein is disordered with extensive branching of the hepatic plates. Sinusoids appear dilated but rarely vesicular. Small lipid droplets are present, occasionally in isolated groups of the liver acini.
4. Some organized hepatic lobules are apparent, but many show disorganization of the radial arrangement of the hepatic plates due to branching. Moderate steatosis is present in at least 50% of the liver acini. The steatosis appears as small lipid inclusions. Sinusoids appear dilated and occasionally vesicular. Some hepatocytes appear hypertrophied.
5. Disruption of the hepatic lobule organization is observed. Extensive steatosis is present in most of the liver acini. Sinusoids are dilated and frequently vesicular. Hepatocytes are hypertrophied with large, pale-staining nuclei.

Hepatocellular degeneration was counted for every field of view of each specimen. The data from the number of cells degeneration was analyzed by analysis of variance and least significant difference to know the difference between treatments.

Results And Discussion

Composition of Tocotrienol Rich Fraction

The composition of vitamin E in this study was similar to that reported by Ahmadi *et al.*³⁴, that TRF composition was tocopherol 37.38%, tocotrienol 10.73%, tocotrienol 20.67%, and tocotrienol 31.25% with vitamin E concentration of 13.01% (230.1 mg/g) or 343.43 IU/g. This study also used commercial vitamin E as a comparison, with vitamin E comprised of d- α -tocopherol. The concentration of tocopherol in that commercial vitamin E was 100 IU or 67 mg per soft capsule.

Liver MDA Level

Decomposition of lipid hydroperoxides leads to a wide variety of end products, one of which is malondialdehyde (MDA), which is now accepted as a reliable marker of lipid peroxidation^{35,36}. Liver MDA level is a by-product of lipid peroxidation³⁷ and is generated by oxidative attacking on membrane phospholipids and circulating lipids³⁸. MDA is a parameter for antioxidant status and a marker for lipid peroxidation in the liver.

Hepatoprotective effect of TRF was shown by the ability to inhibit lipid peroxidation in the liver that indicated by lower MDA level. Control group had similar liver MDA level to that of group force fed by TRF 0 and 25 mg/kg bw/day. In this experiment, control group showed the highest MDA level, although statistically this level was not different to TRF 0 mg/kg bw/day or non TRF treated-lipid peroxidation group. Presumably, high MDA level in the liver of control group related to many factors that affecting oxidative stress such as physiological conditions that led to rapid metabolism and producing high rate of reactive oxygen species.

Thermally oxidized frying oil had high peroxide number. Oxidized oil is a source of lipid hydroperoxides. Liver has a function for lipid metabolism and involved in metabolism of lipid peroxidation from ingested thermally oxidized frying oil. According to Richardson *et al.*³⁹ the lipid peroxidation assay measures malondialdehyde, a by-product of lipid peroxidation, and can be used as a quantitative measurement of the

extent of oxidative damage an organ. Oxidative stress in the liver is a consequence of increased production of free radicals and decreased capacity of antioxidant defense systems in hepatocytes⁴⁰.

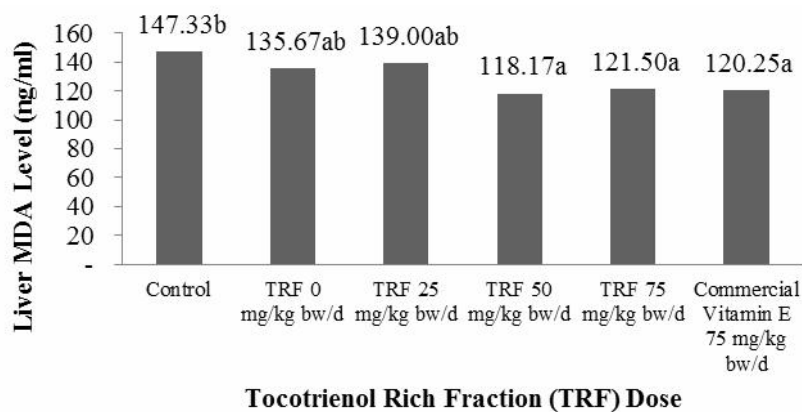


Figure 1. Liver MDA level of groups of rats treated by various doses of TRF and commercial vitamin E

Figure 1 showed that groups of rats fed by TRF 50 and 75 mg/kg bw/day had lower liver MDA level, as well as group treated by commercial vitamin E at dose of 75 mg/kg bw/day. TRF at lower dose showed slightly lower MDA level than commercial vitamin E, that indicating TRF was more effective in inhibition lipid peroxidation. Commercial vitamin E contained d- α -tocopherol. Alpha tocopherol, a chain-breaking antioxidant that traps peroxy free radicals, is the principal and most potent lipid-soluble antioxidant in plasma and LDL. Alpha tocopherol has proven to be effective in preventing lipid peroxidation and other radical-driven oxidative events^{41, 42}. According to Packer *et al.*²⁵, vitamin E is incorporated into cellular membranes in which it effectively inhibits the peroxidation of lipids. Both tocopherols and tocotrienols scavenge the chain-propagating peroxy radical.

Moreover, Packer *et al.*²⁵ stated that when comparing the effectiveness of different vitamin E homologues, at least two factors must be considered, i.e., the substituents on the chromanol nucleus and the properties of the side chain. In homogeneous solutions, the reaction rate constant depends mainly on the number of methyl groups on the nucleus. In membranes, the mobility of the molecule also becomes important, and this depends on the structure of the hydrophobic side chain. The study of Serbinova *et al.*⁴³ showed that tocotrienol had peroxy scavenging activity in liposomes 1.5-fold higher than tocopherol. Also, tocotrienol had the ability to protect liver against lipid peroxidation 40 times higher than tocopherol. Serbinova *et al.*⁴³ suggested that this difference related to the tail structure of tocotrienol and tocopherol, beside the chromanoxyl radical of α -tocotrienol (α -tocotrienoxyl) has been found to be recycled in membranes and lipoproteins more quickly than the corresponding α -tocopheroxyl radical.

Slight increase in MDA level of group of rats treated by TRF 75 mg/kg bw/day showed that in the high dose, TRF was less effective in preventing lipid peroxidation. At high doses, it is possible that TRF induced peroxidation and became prooxidant. Kontush *et al.*⁴⁴ stated that the major mechanism of antioxidative action of tocopherol includes inactivation of one radical (R') by one molecule of α -tocopherol (TocH), with a subsequent scavenging of a second radical by the α -tocopheroxyl radical (Toc') formed non-radical products. It is resulting inactivation of two radicals per one molecule of α -tocopherol underlies the classical antioxidant activity of this compound. This mechanism is operative when free radicals are formed at a relatively high rate, i.e., under strong oxidative conditions^{45, 46}. Kontush *et al.*⁴⁴ postulated that rapid elimination of α -tocopheroxyl radical via reaction with another lipid radical leads to the net antioxidant activity of α -tocopherol. This analysis points out that α -tocopherol should always function as an antioxidant, if the concentration of co-antioxidants is high enough to efficiently recycle α -tocopheroxyl radical back to α -tocopherol. In this study, it was suggested that high dose of TRF produced high tocopheroxyl radical that had oxidative properties and led to high MDA level.

At TRF dose of 25 mg/kg bw/day, liver MDA level did not differ significantly to the dose of 0 mg TRF/kg bw/day. It showed that dose of 25 mg/kg bw/day was not effective to inhibit liver lipid peroxidation.

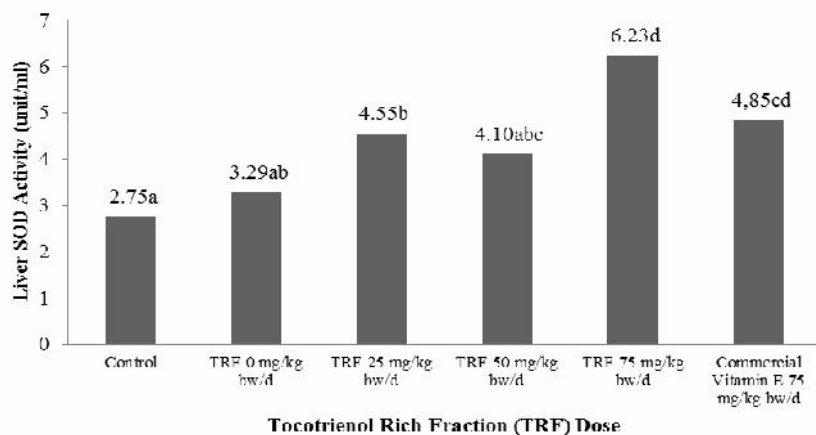


Figure 2. Liver SOD activities of groups of rats treated by various doses of TRF and commercial vitamin E

Liver Superoxide Dismutase (SOD) Activity

Reactive oxygen species is a product of dioxygen metabolism that acts as an electron acceptor. However dioxygen prefers to receive one electron at a time and converts it into a superoxide ion ($O_2^{\bullet-}$). ROS has the ability to oxidize PUFA (polyunsaturated fatty acid) as a constituent of cell membrane. This reaction initiates lipid peroxidation and to limit these harmful effects, an organism requires complex protection – the antioxidant system. This system consists of antioxidant enzymes (catalase, glutathione peroxidase, superoxide dismutase) and non-enzymatic antioxidants (e.g. vitamin E [tocopherol], vitamin A [retinol], vitamin C [ascorbic acid], glutathione, and uric acid). SOD is the major defence upon superoxide radicals and is the first defence line against oxidative stress. SOD represents a group of enzymes that catalyse the dismutation of $O_2^{\bullet-}$ and the formation of H_2O_2 ⁴⁷. Liver SOD activity indicated antioxidant status and oxidative stress condition. High SOD activity revealed good antioxidant status and low lipid peroxidation.

This study showed that TRF had a capability to protect liver from lipid peroxidation that indicated by higher SOD activities of groups of rats treated by TRF (Figure 2). As liver MDA level, control groups showed lower SOD activity that indicated lower antioxidant status compared to lipid peroxidation induced group (group of rats that fed by TRF 0 mg/kg bw/day). This was suggested to relate to stress condition due to other factors such as physiological conditions.

TRF and commercial vitamin E treatments improved liver antioxidant status that indicated by higher SOD activity compared to non-TRF treatment (dose of 0 mg/kg bw/day). The highest liver SOD activity was found at dose of 75 mg/kg bw/day. This study also showed that TRF was better than commercial vitamin E to increase SOD activity because at similar dose (75 mg/kg bw/day) TRF treatment revealed higher SOD activity. TRF comprised mainly by tocotrienols (62.62%) and the remaining was tocopherol (37.38%). Meanwhile, commercial vitamin E only contained tocopherol. Tocopherols and tocotrienols although have almost similar molecular structure, but their antioxidant activity is slightly different. According to Packer *et al.*²⁵ tocopherols and tocotrienols are part of an interlinking set of antioxidant cycles, which has been termed the antioxidant network. The antioxidant activity of tocotrienols is higher than that of tocopherols and efficiently combat oxidative stress. In rat liver microsomes, the efficacy of α -tocotrienol to protect against Fe(II)-NADPH-induced lipid peroxidation was 40 times higher than that of α -tocopherol. α -Tocotrienol also was 6.5 times more effective in the protection of cytochrome P-450 against oxidative damage.

SOD activity of non TRF treated group (0 mg/kg bw/day) was not significantly ($p=0.05$) different to that of groups of rats treated by TRF 25 and 50 mg/kg bw/day. TRF dose of 50 mg/kg bw/day did not differ

significantly to commercial vitamin E with dose of 75 mg/kg bw/day. It strengthened the evidence that TRF had better *in vivo* antioxidant activity and was better to protect liver from lipid peroxidation.

This study showed that increase in SOD activity was in accordance to decrease in MDA level. SOD enzymes catalyze the dismutation of superoxide radical into hydrogen peroxide (H_2O_2) and molecular oxygen (O_2) and consequently present an important defense mechanism against superoxide radical toxicity⁴⁸. Increasing SOD activity leads to high decomposition rate of superoxide radicals and prevents MDA formation. Therefore, MDA level also decreases. According to Jyothi *et al.*⁴⁸, the ratio of MDA to SOD is an index for oxidative stress.

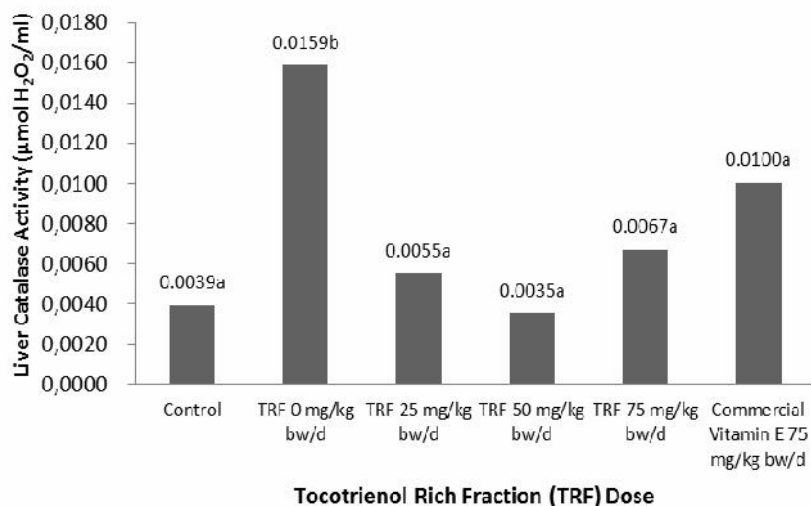


Figure 3. Liver catalase activities of groups of rats treated by various doses of TRF and commercial vitamin E

Liver Catalase Activity

Catalase or CAT is present in every cell and in particular in peroxisomes, which are the cell structures that use oxygen in order to detoxify toxic substances and produce H_2O_2 . Catalase converts H_2O_2 into water and oxygen. CAT has an important action with lower H_2O_2 concentration^{47, 49}. The SODs convert superoxide radical into hydrogen peroxide and molecular oxygen (O_2), whereas the catalase and peroxidases convert hydrogen peroxide into water and, in the case of catalase, into oxygen and water. The net result is that two potentially harmful species, superoxide and hydrogen peroxide, are converted to water. Other compartmentalized antioxidant enzymes include catalase, which is found in peroxisomes and the cytoplasm, and GPx, which can be found in many subcellular compartments including the mitochondria and the nucleus depending on the family member. Thus, the many forms of each of these enzymes reduce oxidative stress in the various parts of the cell⁵⁰.

This study showed that TRF treatments increased catalase activities indicating by low H_2O_2 concentration (Figure 3). Control group of rats or non peroxidation induced group showed low level of H_2O_2 that meant low oxidation and only small amount of H_2O_2 produced. Conversely, non TRF treated group showed the highest H_2O_2 level that indicated oxidative stress condition.

Liver H_2O_2 of groups of rats treated by TRF and commercial vitamin E was not significantly different ($\alpha=0.05$) to that of control group. It meant that vitamin E intake effectively prevented peroxidation thus producing low level H_2O_2 . This study also showed that TRF was more effective antioxidant than commercial vitamin E. All TRF treated groups had lower H_2O_2 concentration than that of commercial vitamin E treated group.

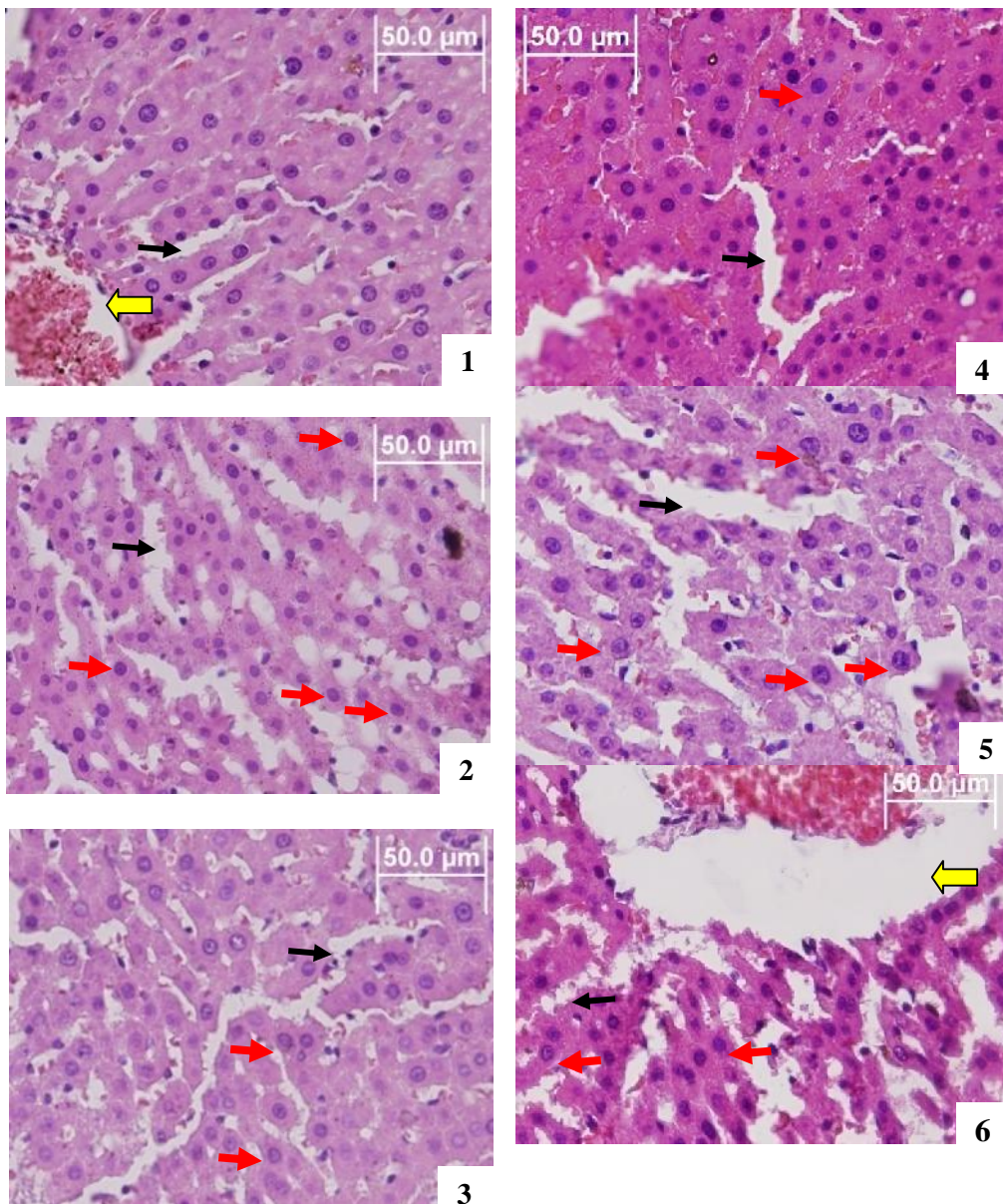





Figure 4. Histopathology of hepatic cells of rats treated by various doses of TRF and commercial vitamin E. Magnification of 400x and stained by hematoxyllin – (1) control, indicated normal cells; (2) TRF dose of 0 mg/kg bw/day, showed cell degeneration and dilated sinusoid in hepatic lobule; (3) TRF dose of 25 mg/kg bw/day showed normal cells arrangement in hepatic lobule; (4) TRF dose of 50 mg/kg bw/day indicated normal cells but also contained cell degeneration; (5) TRF dose of 75 mg/kg bw/day showed dilated sinusoid at hepatic lobule and some cells were ballooning; (6) commercial vitamin E with dose of 75 mg/kg bw/day showed normal cells arrangement, but some cells were degeneration.  = central vein;  = sinusoid;  = cell degeneration with ballooning nuclei and pale cytoplasm (hydropic degeneration).

Liver Histopathology and Degenerated Hepatic Cells

Generally, each components of hepatic tissues of rats treated by TRF, commercial vitamin E, and control could be observed apparently (Figure 4). Hepatic lobule was still apparent, and central vein was surrounded by well organized hepatic cells in radial arrangement. The difference among treatments was in the density and stain of hepatocytes, and hepatocyte nucleus size as well. It was not observed the death of cells or necrosis that was indicated by cell lysis, shrinkle nuclei, the very pale-stained hepatocytes, and disappearing of cell nuclei⁵¹.

Based on the the scale of Sun *et al.*³³, the liver of rats of control group, TRF dose of 25 mg/kg bw/day, TRF dose of 50 mg/kg bw/day, and commercial vitamin E treated groups revealed scale 1. In this scale, the hepatic morphology did not alter significantly, the hepatic tissue was in closely arrangement, the hepatic lobule was still apparent, hepatic plates were radial and well organized, and hepatocyte nuclei was also still present apparently.

Liver of rats that treated with TRF dose of 0 mg/kg bw/day and 75 mg/kg bw/day was catagorized as scale 2. Dilation of sinusoid was present and the hepatic plates apparently surrounded central vein. Some parts of tissue area contained pale-stained hepatocytes. However, the fat lobules indicating steatosis were not present. According to Lima *et al.*⁵² and Liew *et al.*⁵³ steatosis represented the basic injury and was associated with hepatocellular ballooning degeneration. Therefore, it could be concluded that oxidative stress induced by thermally oxidized frying oil intake caused only sublethal injury or reversible effect. It meant the hepatocytes would recover if the intake of thermally oxidized frying oil was ended.

Hepatocellular ballooning occurred if the hepatocytes were not able to maintain ion balance. This phenomenon was early manifestation of cell injuries. Hydrophic degeneration was a longterm effect of hepatocellular ballooning indicated by huge liquid accumulation. Therefore, hepatocyte degeneration were indicated by bigger cell appearance⁵².

Cell degeneration was counted for every fields of view under microscopic observation. Each slides was represented by 15 fields of view and the number of cell degeneration was avaraged. Statistical analysis revealed that the number of cells degeneration was affected by TRF treatments. The highest number of cells degeneration was found at TRF dose of 75 mg/kg bw/day, that this number was not significantly different to that of non TRF treatment (o mg/kg bw/day, peroxidation induced). The lowest number of cells degeneration was obtained at TRF dose of 50 mg/kg bw/day. It was supposed that TRF dose of 75 mg/kg bw/day led to oxidaton because vitamin E might become a prooxidant at high dose. Average number of cell degeneration of liver of rats treated by TRF dose of 25 mg/kg bw/day did not differ significantly to that of commercial vitamin E at dose of 75 mg/kg bw/day. This finding support the evidence that TRF was more effective than commercial vitamin E to protect liver from degeneration.

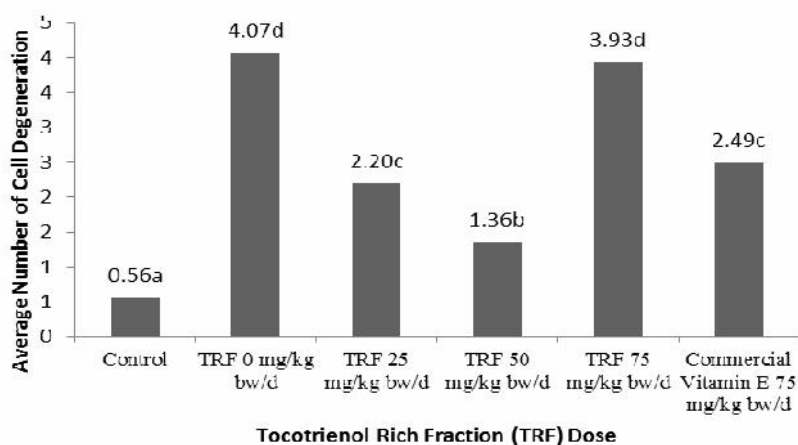


Figure 5. Cell degeneration of liver of rats treated by various doses of TRF and commercial vitamin E

Conclusion

Tocotrienol rich fraction (TRF) from palm fatty acid distillate was an effective antioxidant to protect liver from peroxidation, indicated by decreasing liver MDA level, increasing liver SOD activity, and increasing liver catalase activity, as well as impairment in hepatocytes. The effective dose of TRF was 50 mg/kg bw/day. At higher dose (75 mg/kg bw/day) TRF possibly became prooxidant that indicated by liver of rats treated by TRF dose of 75 mg/kg bw/day had the highest average number of cells degeneration. TRF was more effective in protecting liver from peroxidation than commercial vitamin E.

Acknowledgement

The authors would like to thank to Directorate General of Higher Education, Ministry of Education and Culture, Republic of Indonesia for funding this research through IMHERE Staff Research Grant.

References

1. Murphy R.C., Free-radical-induced oxidation of arachidonoyl plasmalogen phospholipids: antioxidant mechanism and precursor pathway for bioactive eicosanoids, *Chem. Res. Toxicol.*, 2001, 14: 463.
2. Reddy G.B., Khandare A.L., Reddy P.Y., Rao G.S., Balakrishna N., and Srivalli I., Antioxidant defense system and lipid peroxidation in patients with skeletal fluorosis and in fluoride-intoxicated rabbits, *Toxicol. Sci.*, 2003, 72, 363–368.
3. Halliwell B. and Chirico, S., Lipid peroxidation: its mechanism, measurement, and significance, *Am. J. Clin. Nutr.*, 1993, 57, 715S-724S.
4. Niki E. and Noguchi N., Dynamics of antioxidant action of vitamin E, *Acc. Chem. Res.*, 2004, 37, 45-51.
5. Musalmah M., Nizam M.Y., Fairuz A.H., Noor Aini A.H., Azian A.I., Gapor M.T., and Wan Ngah W.Z., Comparative effects of palm vitamin E and α tocopherol on healing and wound tissue antioxidant enzyme levels in diabetic rats, *Lipids*, 2005, 40, 575-580.
6. Ammouce A., Rouaki F., Bitam A., and Bellai M.M., Effect ingestion of thermal oxidized sunflower oil on fatty acid composition and antioxidant enzymes of rat liver and brain in development, *Ann. Nutr. Metab.*, 2002, 46, 268-275.
7. Gonenc A., Erten D., Aslan S., Akinci M., Sximssek B., and Torun M., Lipid peroxidation and antioxidant status in blood and tissue of malignant breast tumor and benign breast disease, *Cell Bio. Int.*, 2006, 30, 376-380.
8. Hamden K., Carreau S., Ellouz F., Masmoudi H., and El Feki A., Improvement effect of green tea on hepatic dysfunction, lipid peroxidation and antioxidant defence depletion induced by cadmium, *African Journal of Biotechnology*, 2009, 8, 4233-4238.
9. Manimaran A. and Rajneesh C.P., Activities of antioxidant enzyme and lipid peroxidation in ovarian cancer patients, *Academic Journal of Cancer Research*, 2009, 2, 68-72
10. Mohan S.K. and Priya V., Lipid peroxidation, glutathione, ascorbic acid, vitamin E, antioxidant enzyme and serum homocysteine status in patients with polycystic ovary syndrome, *Biology and Medicine*, 2009, 1, 44-49.
11. Meydani, M., Effect of functional food ingredients: vitamin E modulation of cardiovascular diseases and immune status in the elderly, *Am. J. Clin. Nutr.*, 2000, 71, 1665s-1668s.
12. Choi Y. and Lee, J., Antioxidant and antiproliferative properties of a tocotrienol-rich fraction from grape seeds, *Food Chem.*, 2009, 114, 1386–1390.
13. Mitei Y.C., Ngila J.C., Yeboah S.O., Wessjohann L., and Schmidt J., Profiling of phytosterol, tocopherols and tocotrienols in selected seed oils from botswana by GC-MS and HPLC, *J. Am. Oil Chem. Soc.*, 2009, 86, 617-625
14. Yoshida Y. and Niki E., Tocotrienols and Tocopherols in Solution and Membranes: Chemical and Physical Effects, *In Tocotrienols*, Watson R.R. and Preedy V.R. (ed), CRC Press, Boca Raton, 2009.

15. Ikeda S., Uchida T., Ichikawa T., Watanabe T., Uekaji Y., Nakata D., Terao K., and Yano T., Complexation tocotrienol with β -cyclodextrin enhances intestinal absorption of tocotrienol in rats, *Biosci. Biotechnol. Biochem.* 2010, 74, 1452-1457
16. Liu D., Shi J., Posada L.R., Kakuda Y., and Xue S.J., 2008, Separating tocotrienol from palm oil by molecular distillation, *Food Reviews International*, 2008, 24, 376-391.
17. Qureshi A.A., Mo H., Packer L., and Peterson D.M., Isolation and identification of novel tocotrienols from rice bran with hypocholesterolemic, antioxidant, and antitumor properties, *J. Agric. Food Chem.*, 2000, 48, 3130-3140.
18. Jang S. and Xu Z., Lipophilic and hydrophilic antioxidants and their antioxidant activities in purple rice bran, *J. Agric. Food Chem.*, 2009, 57, 858–862.
19. Cunha S.C., Amaral J.S., Fernandes J.O., and Oliveira M.B.P.P., Quantification of tocopherols and tocotrienols in Portuguese olive oils using hplc with three different detection systems, *J. Agric. Food Chem.*, 2006, 54, 3351-3356.
20. Kallio H., Yang B., and Peippo P., Effects of Different origins and harvesting time on vitamin C, tocopherols, and tocotrienols in sea buckthorn (*Hippophaë rhamnoides*) berries, *J. Agric. Food Chem.*, 2002, 50, 6136-6142.
21. Law K. and Thiagarajan T., Palm Oil – of Edible Oil Tomorrow in Erickson D.R. (ed). *Edible Fats and Oils Proceeding–Basic Principles and Modern Practices*, World Conference Proceedings, Am Oils Chem Soc., Champaign, Illinois-USA, 1990.
22. Hakim, A.M., Low temperature solvent crystallization on vitamin E concentrate preparation from palm fatty acid distillate, Bachelor Degree Thesis. Department of Food Science and Technology, Brawijaya University, Malang, Indonesia, 2009.
23. Hanani, F., Fraction of vitamin E rich in tocotrienol from palm fatty acid distillate prepared by low temperature solvent crystallization, Bachelor Degree Thesis. Department of Food Science and Technology, Brawijaya University, Malang, Indonesia, 2009.
24. Serbinova, E. A. and Packer L., Antioxidant properties of α -tocopherol and γ -tocotrienol, *Methods Enzymol.*, 1994, 234, 354–366.
25. Packer L., Weber S.U., and Rimbach G., Molecular Aspects of α -tocotrienol antioxidant action and cell signaling, *J. Nutr.*, 2001, 13, 369S–373S.
26. Panozzo P.M., Basso D., Balint L., Biasin M.R., Bonvicini P., and Metus P., Altered lipid peroxidation/glutathione ratio in experimental extrahepatic cholestasis, *Clin Exp Pharmacol Physiol.*, 1995, 22, 266-271.
27. Assady A.F., Golestani A., and Esharghian M.R., Superoxide dismutase (SOD) enzyme activity assay in *Fasciola* spp. parasites and liver tissue extract, *Iranian J. Parasitol.*, 2011, 6, 17-22.
28. Ahmadi K., Kumalaningsih S., Wijana S., and Santoso I., Optimizing vitamin E purification from unsaponifiable matter of palm fatty acids distillate by low temperature solvent crystallization, *Journal of Food Science and Engineering*, 2012, 2, 557-563.
29. Ball G.F.M., *Fat-Soluble Vitamin Assays in Food Analysis*, Elsevier Applied Science, London, 1989, 234-257.
30. Heatkiewicz, *Clinical Laboratory Animal Medicine*, 3ed, State Avenue, 2007.
31. Krishnaraju A.V., Rao C.V., Rao T.V.N., Reddy K.N., and Trimurtulu G., *In vitro* and *in vivo* antioxidant activity of *Aphanamixis polystachya* bark, *American Journal of Infectious Diseases*, 2009, 5, 60-67.
32. Sumanth M. and Rana A.C., *In vivo* antioxidant activity of hydroalcoholic extract of *Taraxacum officinale* roots in rats, *Research Letter, Indian J. Pharmacol.*, 2006, 38, 54-55.
33. Sun G.Y., Xia J., Xu J., Allenbrand B., Simonyi A, Rudeen P.K., and Sun A.Y., Dietary supplementation of grape polyphenols to rats ameliorates chronic ethanol-induced changes in hepatic morphology without altering changes in hepatic lipids, *J. Nutr.*, 1999, 129, 1814–1819.
34. Ahmadi K., Kumalaningsih S., Wijana S., and Santoso I., Antioxidative effect of tocotrienol rich fraction from palm fatty acid distillate on oxidative stress, *Food and Public Health*, 2013, 3, 130-136.
35. Ohkawa H., and Ohishi N., Assay for lipid peroxides in animal tissues by thiobarbituric acid reaction, *Anal. Biochem.* 1979, 95, 351-358.

36. Turgut G., Enli Y., Kaptanoglu B., Turgut S., and Genc O., Changes in the level of MDA and GSH in mice serum, liver and spleen after aluminium administration, *Eastern Journal of Medicine*, 2006, 11, 7-12.
37. Jackson P., Loughrey C.M., and Lightbody J.H., Effect of hemodialysis on total antioxidant capacity and serum antioxidants in patients with chronic renal failure, *Clin. Chem.*, 1995, 41, 1135–1138.
38. Djukic´ C.D., Curcic´ J.M., Plamenac B.Z., Ninkovic´ M., Malicevic´ Z., and Matovic´ V., Relation between lipid peroxidation and iron concentration in mouse liver after acute and subacute cadmium intoxication, *Journal of Trace Elements in Medicine and Biology*, 2008, 22, 66–72.
39. Richardson N., Gordon A.K., Muller W.J., Pletschke B.I., and Whitfield, A.K., The use of liver histopathology, lipid peroxidation and acetylcholinesterase assays as biomarkers of contaminant-induced stress in the Cape stumpnose, *Rhabdosargus holubi* (Teleostei: Sparidae), from selected South African estuaries, *Water SA*, 2010, 36, 407-415.
40. Ostojic J.N., Mladenovic D., Ninkovic M., Vučević D., Bondzic K., Vukicevic R.J., and Radosavljevic T., The effects of cold-induced stress on liver oxidative injury during binge drinking, *Human and Experimental Toxicology*, 2012, 31, 387–396.
41. Kaul N., Devaraj S., and Jialal I., Alpha-tocopherol and atherosclerosis, *Exp Biol, Med. (Maywood)*, 2001, 226, 5–12.
42. Kır H.M., Dillioglugil M.O., Tugay M., Eraldemir C., and Özdoğan H.K., Effects of vitamins E, A and D on MDA, GSH, NO levels and SOD activities in 5/6 nephrectomized rats, *Am. J. Nephrol.*, 2005, 25, 441–446.
43. Serbinova E., Kagan V., Han D., and Packer L., Free radical recycling and intramembrane mobility in the antioxidant properties of alpha-tocopherol and alpha-tocotrienol, *Free Radic. Biol. Med.*, 1991, 10, 263–275.
44. Kontush A., Finckh B., Karten B., Kohlschutter A., and Beisiegel U., Antioxidant and prooxidant activity of α -tocopherol in human plasma and low density lipoprotein, *Journal of Lipid Research*, 1996, 37, 1436-1448.
45. Bowry V.M., Mohr D., Cleary J., and Stocker R., Prevention of tocopherol-mediated peroxidation in ubiquinol-10-free human low density lipoprotein, *J. Biol. Chem.*, 1995, 270, 5756-5763.
46. Bowry V.W. and Stocker R., Tocopherol-mediated peroxidation. The prooxidant effect of vitamin E on the radical-initiated oxidation of human low-density lipoprotein, *J. Am. Chem. Soc.*, 1993, 115, 6029-6044.
47. Finaud J., Gérard L., and Filaire E., Oxidative stress: relationship with exercise and training. *Sports Med.*, 2006, 36, 327-358.
48. Jyothi P., Najeeba R., Nandakumar G., and Binitha M.P., A study of oxidative stress in *Paucibacillary* and *Multibacillary leprosy*, *Indian Journal of Dermatology, Venereology and Leprology*, 2008, 74, 80.
49. Antunes F., Derick H., and Cadenas E., Relative contributions of heart mitochondria glutathione peroxidase and catalase to H₂O₂ detoxification in in vivo conditions, *Free Radic. Biol. Med.*, 2002, 33, 1260-1267
50. Weydert C.J. and Cullen J.J., Measurement of superoxide dismutase, catalase and glutathione peroxidase in cultured cells and tissue, *Nature Protocols*, 2010, 5, 51-66.
51. Robbins R.L., Cotran R.S., and Vinay K., *Basic Pathologic of Disease*, W.B. Saunders Company, Toronto, 1999.
52. Lima M.L.R.P., Mourao S.C.O., and Diniz M.T.C., Hepatic histopathology of patients with morbid obesity submitted to gastric bypass, *Obes. Surg.*, 2005, 15, 661-669.
53. Liew P.L., Lee W.J., Lee Y.C, Wang H.H., Wang W., and Lin Y.C., Hepatic histopathology of morbid obesity: concurrence of other forms of chronic liver disease, *Obes. Surg.*, 2006, 16, 1584-1593.

★★★★★