PharmTech

International Journal of PharmTech Research
CODEN (USA): IJPRIF ISSN : 0974-4304
Vol.3, No.4, pp 2162-2168, Oct-Dec 2011

Hepatoprotective Effect of the Ethanolic Extract of *Calocybe indica* on Mice with CCl_4 Hepatic Intoxication

Soumya Chatterjee, Anwesha Dey, Riddhi Dutta, Sandip Dey, Krishnendu Acharya*

Molecular and Applied Mycology and Plant Pathology Laboratory, Department of Botany, University of Calcutta, 35, Ballygunge Circular Road, Kolkata-700 019, West Bengal, India.

Corres. Author: krish_paper@yahoo.com
Telephone: 08013167310

Abstract: This study was undertaken to investigate the hepatoprotective activity of ethanolic extract of a wild edible mushroom (*Calocybe indica*) against carbon tetrachloride (CCl_4) induced hepatic damage in mice. Oral administration of CCl_4 (2.5 ml/ kg body weight/ day) induced chronic hepatotoxicity resulting elevated serum levels of glutamate pyruvate tranaminase (SGPT), glutamate oxaloacetate transaminase (SGOT), alkaline phosphatase (ALP) and bilirubin content. The substantially elevated serum marker enzyme levels were restored towards normalization by the extract treatment when administered at a dose of 150 mg/kg body wt once daily. Silymarin was used as standard reference drug. The hepatic antioxidant status such as superoxide dismutase (SOD), catalase (CAT), reduced glutathione (GSH) levels were reduced in the CCl_4 alone treated animals with subsequent increase in lipid peroxidation. Administration of the extract challenge restored the hepatic antioxidant status. Furthermore, histopathogical studies confirmed the hepatoprotective effect conferred by the ethanolic extract of *C. indica*. The findings thus suggested ethanolic extract of *C. indica* protects CCl_4 induced chronic hepatotoxicity in mice by restoring the liver antioxidant status.
Keywords: *Calocybe indica*, Carbon tetrachloride, Hepatoprotective effect, Lipid peroxidation, Mushroom.

1. INTRODUCTION

The liver is the main organ responsible for multitude of essential functions and plays an essential role in the metabolism of foreign compounds entering the body. Human beings are exposed to these compounds through environmental exposure, consumption of contaminated food or during exposure to chemical substances in the occupational environment. All these compounds produce a variety of toxic manisfestation (1). Liver injuries induced by various hepatotoxins have been recognized as a major toxicological problem for years (2). Carbon tetrachloride (CCl_4) is a xenobiotic producing hepatotoxicity in human beings and animals (3, 4). CCl_4 mediated hepatocyte injury is characterized by centrilobular necrosis followed by hepatic fibrosis (5). CCl_4 is biotransformed to a trichloromethyl radical by cytochrome P450 system in liver microsomes, and consequently causes lipid peroxidation of membranes that leads to liver injury (6-8). Trichloromethyl ($CCl_3^{\cdot}$) radical even reacts with reduced glutathione (GSH) and causes various pathological and toxicological manifestations (9). CCl_4

has been shown to activate Kupffer cells by increasing intercellular Ca^{2+} concentration, causing release of harmful cytokines that contribute to the death of hepatocytes and oxidative stress (10, 11). Antioxidants play a crucial role in hepatoprotective ability and hence the search for crude drugs of natural origin with this property has become a central focus of study of hepatoprotection today (12). Inspite of tremendous advances in modern medicine no effective drugs are available, which stimulate liver functions and offer protection to the liver from the damage or help to regenerate hepatic cells (13). In absence of reliable liver- protective drugs in modern medicine, a large number of medicinal preparations are recommended for the treatment of liver disorders and quite often claimed to offer significant relief (14). Mushrooms are macrofungi, and they have had a notable place in folk medicine throughout the world since ancient times. Attempts have been made in many parts of the world to explore the use of mushrooms and their metabolites for the treatment of a variety of human sufferings (15). Besides being a healthy food, mushrooms are used as ailments for the persons suffering from cancer, coronary heart disease, diabetes, high blood pressure, constipation, renal failure etc (16). Mushrooms have been known to be potential source of antioxidants and also capable of strong inhibition of lipid peroxidation (17-19). *Calocybe indica* of the Family Lyophyllaceae, a wild edible mushroom generally grows solitary or sometimes in groups in moist soil or at shade of trees. Here, an attempt has been made to evaluate the hepatoprotective potency against CCl_4 induced hepatic damage in mice of ethanolic extract of *C. indica*.

2. EXPERIMENTAL

Sample collection and preparation

Basidiocarps of *Calocybe indica* were collected from the forest and local market of South 24 Parganas, West Bengal, India.

Fresh mushrooms were randomly selected into three samples of 150 g each and air-dried in an oven at 40°C for 48 h. Dried powdered mushroom sample was extracted by stirring with 200 ml of ethanol at 30°C for 24 h at 150 rpm and filtering through Whatman No. 4 filter paper. The residue was then extracted twice with another 200 ml of ethanol as described above. The total extract was then rotary evaporated to dryness at 40°C and redissolved in ethanol to a concentration of 10 mg/ml and stored at -20°C for further use (20).

Animals

Healthy male Swiss albino mice of approximately same age weighing about 20 g were used for the study. They were fed with standard diet and water *ad libitum* and housed in polypropylene cages maintained under standard condition (12 h light/dark cycle; 25 ± 3°C, RH 35-60%). The animals were maintained according to the guidelines recommended by Animal Welfare Board and approved by our institutional ethics committee. All procedures complied with the Declaration of Helsinki, as revised in 1996.

Acute toxicity studies

The acute toxicity study for *C. indica* ethanolic extract was performed using Swiss albino mice. The animals were fasted overnight prior to the experiment and maintained under standard conditions. The extract were administered orally in increasing dose and found safe up to dose of 3000 mg/kg body wt.

CCl_4 induced hepatotoxicity and assessment of liver damage

The animals were divided into 4 groups of 6 animals each. Group I, which served as normal control received saline (5 ml/kg body wt/day, p.o.). Group II, the positive control was given CCl_4 in paraffin oil (1:1, 2.5 ml/kg body wt/day, p.o.) once daily for 7 consecutive days. Group III received standard drug Silymarin (100 mg/kg body wt, p.o.) once daily for 7 days and simultaneously administered with CCl_4 with equal volume of paraffin oil. Group IV received ethanolic extract of *C. indica* (150 mg/kg body wt, p.o) once daily for 7 consecutive days, simultaneously with equal mixture of CCl_4 and paraffin oil. The animals were sacrificed 24 h after the last treatment of CCl_4. Blood was collected, allowed to clot and serum was separated by centrifugation at 2500 rpm for 15 min and biochemical investigations were carried out. The liver was excised for the determination of antioxidants and fixed in 10% buffered formalin for histopathological assessment of liver damage.

Determination of hepatoprotective effect

As a marker of hepatocyte necrosis, the activities of serum hepatic marker enzymes namely, serum glutamate pyruvate transaminase (SGPT) (21), serum glutamate oxaloacetate transaminase (SGOT) (21), total and direct bilirubin (22) and alkaline phosphatase (ALP) (23) were assayed using assay kits (Span Diagnostic, Surat).

Evaluation of antioxidant status

Liver samples were dissected out and washed immediately with ice- cold saline to remove as much blood as possible. Liver homogenates (10% w/v) were prepared in cold PBS (50 mM, pH 7). The homogenate was centrifuged at 5000 × g for 10 min in a centrifuge at 4°C, and after removal of the cell debris, the supernatant was used for the assay of superoxide

dismutase (SOD) (24), catalase (CAT) (25), malondialdehyde (MDA) (26) and estimation of GSH (27). Protein was determined by the method of Lowry *et al* (28).

Histopathological examination

Liver tissue was dissected out and fixed in 10% formalin, dehydrated in ethanol gradient (30-100%), cleared in xylene and then embedded in paraffin. Microtome sections of 4 µm thickness were prepared from each liver and stained with hematoxylin-eosin (H&E). The sections were observed microscopically for assessment of necrosis, fatty infiltration, fibrosis, lymphocyte infiltration, and so forth.

Table 1: **Effect of *C. indica* ethanolic extract on biochemical parameters of serum in mice. Values represented as means ± SD from three independent observations.**

Group	Treatment	SGPT (IU/ l)	SGOT (IU/ l)	ALP (KA)	TB (mg/dl)	DB (mg/dl)
Group I	Normal	42.0 ± 11.7	52 ± 12	7.53 ± 0.33	0.708 ± 0.006	0.092 ± 0.006
Group II	CCl_4	128.0 ± 29.4	112 ± 21	14.47 ± 0.34	1.518 ± 0.008	0.429 ± 0.005
Group III	Silymarin + CCl_4	83.67 ± 12	72.67 ± 9.3	8.17 ± 0.49	0.735 ± 0.007	0.126 ± 0.005
Group IV	Ethanolic extract + CCl_4	94.67 ± 14.2	80.6 ± 15	9.5 ± 0.22	0.835 ± 0.01	0.142± 0.004

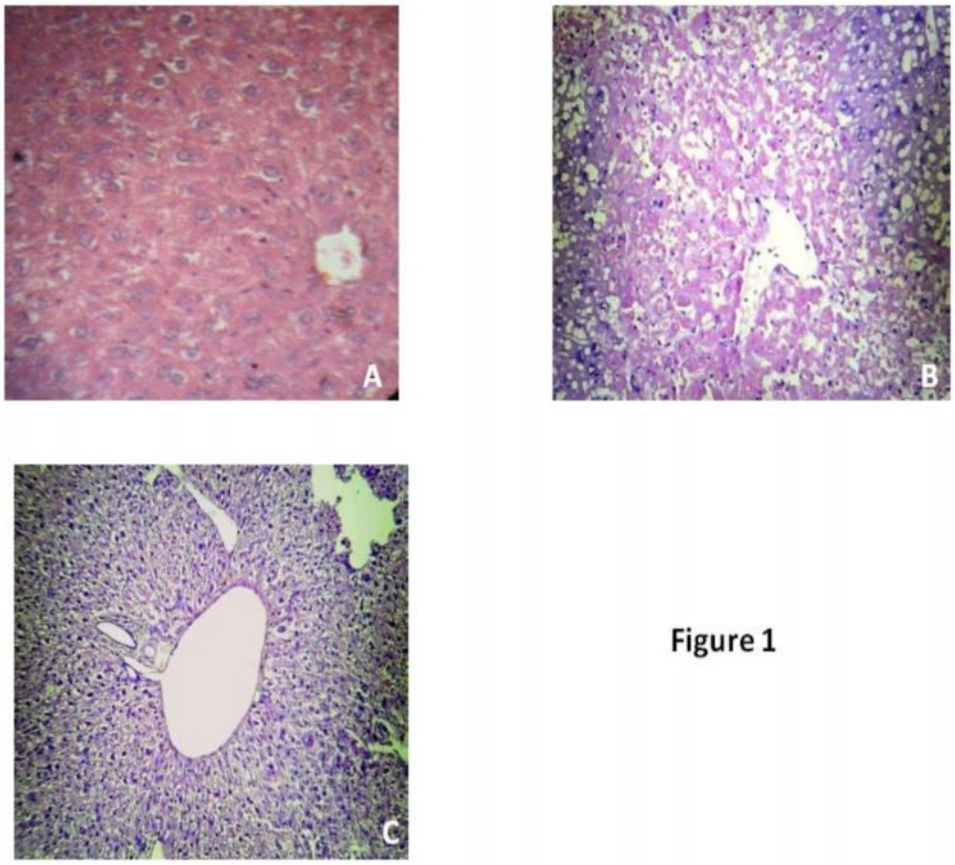

Figure 1

Figure 1: Hepatoprotective effect of ethanolic extract of *C. indica* on CCl_4 induced pathological changes in mice liver. Liver sections stained with H & E. (A) Liver section of normal mice. (B) Liver section of CCl_4 treated mice. (C) Liver section of mice treated with CCl_4 + Ethanolic extract (150 mg/ kg body wt).

Table 2: **Effect of *C. indica* ethanolic extract on liver MDA, SOD, CAT and GSH**. **Values represented as means ± SD from three independent observations.**

Group	Treatment	MDA (nmol/mg)	GSH (µg/mg)	SOD (U/mg)	CAT (µ mole/ min/ mg protein)
Group I	Normal	150.3 ± 3.12	0.820 ± 0.044	7.54 ± 0.79	219.43 ± 6.13
Group II	CCl_4	239 ± 5.23	0.307 ± 0.051	4.39 ± 0.50	79.53 ± 4.24
Group III	Silymarin + CCl_4	154.42 ± 3.73	0.681 ± 0.039	6.18 ± 0.42	197.69 ± 3.72
Group IV	Ethanolic extract + CCl_4	160.5 ± 2.96	0.450 ± 0.047	5.83 ± 0.56	185.64 ± 2.65

3. RESULTS

Acute toxicity studies

The ethanolic extract of *C. indica* did not show any sign and symptoms of toxicity and mortality up to 3000 mg/ kg body wt dose.

Hepatoprotection

The hepatoprotective effects of ethanolic extract of *C. indica* on CCl_4 induced hepatic injury in mice are shown on Table 1. Chronic exposure to CCl_4 revealed elevated liver function indices such as SGPT, SGOT and ALP compared to the normal set. The increased activity of the serum marker enzymes may explain cell membrane breakdown and death (29). The SGPT and SGOT activities in CCl_4 alone treated mice were 128.0 ± 29.4 and 112.0 ± 21 IU/L respectively. The activity was moderately lowered by ethanolic extract treatment. Serum transaminases (SGPT and SGOT) was inhibited by 26.04% and 28.04% respectively compared with control group animals whereas the extract showed inhibition of 34.35% in ALP level with respect to the control set. The serum total and direct bilirubin levels were also elevated in the CCl_4 alone treated groups thereby indicating hepatic damage (30). Treatment with ethanolic extract in group IV lowered the levels, comparable to standard drug Silymarin and towards normalization.

Antioxidant status in liver

A marked increase in the levels of MDA was found in the livers of animals in CCl_4 intoxicated group II when compared to the normal set (Table 2). Treatment with the extract in group IV resulted in lowering of MDA comparable with positive control set. The activities of SOD and CAT was observed to be decreased on CCl_4 intoxication, whereas treatment with extract appeared to exert a beneficial effect since the hepatic antioxidant level is restored to a extent compared to normal and drug control groups. In the CCl_4 intoxicated group II, SOD and CAT were depleted to 4.39 ± 0.50 U/mg and 79.53 ± 4.24 µmole/ min/ mg protein respectively. The reduced levels were ameliorated to values as 5.83 ± 0.56 U/mg and 185.64 ± 2.65 µmole/ min/ mg protein in the extract treated groups. GSH was also found to be augmented by our extract (Table 2), which is a sign of improved hepatic function.

Histopathological observations

Histopathological observations showed severe necrosis, fatty changes, fibrosis, broad infiltration of lymphocytes and loss of cellular boundaries in the hepatocyte of CCl_4 alone treated animals (Figure 1). The histological architecture of liver sections of mice treated with the ethanolic extract showed more or less normalized lobular pattern almost comparable to normal and silymarin treated set with well preserved cytoplasm, prominent nucleus and visible central veins.

4. DISCUSSION

CCl_4 induced hepatic injuries are commonly used models for hepatoprotective drug screening (31). Results of the current study reveal the hepatoprotective activity of the ethanolic extract of *C. indica* against chronic hepatotoxicity induced by CCl_4. The extent of hepatic damage is assessed by the level of increased cytoplasmic enzymes (SGPT, SGOT and ALP), serum bilirubin content in circulation (32) and by histopathological examinations. The experimental damage produced by CCl_4 intoxication resembles viral hepatitis histologically (33). Treatment with the extract lowers serum transaminases indicating stabilization of plasma membrane as well as repair of hepatic injury. The elevated serum ALP activity was due to the intrahepatic cholestasis (34), which was reduced in the extract-treated animals. These effects are in agreement with the commonly accepted view that serum levels of transaminases return to normal with the healing of hepatic parenchyma and regeneration of hepatocytes (35). Even pathological alteration in biliary flow is reflected by the enzyme ALP (36). Marked increase in serum bilirubin content is also in relation with CCl_4

induced elevation of serum enzymatic activity. The bilirubin content consequent to CCl_4 treatment, indicating the ability of the extract to stabilize biliary dysfunction in mice liver during hepatic injury with CCl_4. The antioxidant status of the hepatocytes was altered in the CCl_4 alone treated animals. The treatment of ethanolic extract of *C. indica* with CCl_4 effectively protected the decline of antioxidant activity. The basis of hepatotoxicity of CCl_4 lies in its metabolism in cytochrome P450 system forming two free radicals. The first metabolite, a trichloromethyl radical, forms covalent adducts with lipids and proteins; it can interact with O_2 to form a second metabolite, a trichloromethylperoxy free radical, or can remove hydrogen atoms to form chloroform. This sequence of events leads to lipid peroxidation and consequent liver injury (37). Administration of CCl_4 alone decreased the activity of CAT and SOD in the liver. Further, the level of GSH was also reduced in the liver. The declined antioxidant enzyme activity is responsible for the increased lipid peroxidation measured as thiobarbituric acid reacting substance MDA, which leads to loss of membrane fluidity, membrane integrity, and finally loss of cell functions of liver (38, 39). This injury to the hepatocytes alters their transport function and membrane permeability, leading to the leakage of enzymes from the cells (40). extract also prevented the elevation of total and direct The treatment of the extract increased the hepatocyte SOD, CAT activities and reduced lipid peroxidation, which could effectively prevent radical mediated loss of membrane integrity. Hence, the extract-treated animals showed reduced transaminases activity in the serum.

Reduced glutathione (GSH) plays a key role in the detoxification of the reactive toxic metabolites of CCl_4; liver necrosis is initiated when reserves of GSH are markedly depleted (41). This is evident from the decreased level of hepatic GSH in animals treated with CCl_4 alone. The level was enhanced moderately in extract plus CCl_4 treated animals. Histopathological studies were performed to provide direct evidence of the hepatotoxicity of CCl_4 and hepatoprotective effect of ethanolic extract of *C. indica*. Marked disruption of the structure of hepatocytes was noted in liver tissue of animals exposed to CCl_4 alone. Only minimal disruption of the structure of hepatocytes was observed in liver tissue sections of animals treated with CCl_4 and extract. This observation complemented the results of the liver enzyme studies. Thus it can be concluded that the ethanolic extract of *Calocybe indica* is able to confer protection against hepatotoxicity induced by CCl_4 in mice, which might be through the antioxidant defense mechanism.

REFERENCES

1. Athar M., Hussain Z.S. and Hassan N., Drug metabolizing enzymes in liver. In: Rana S.V.S. (Eds) Liver and Environmental Xenobiotics, Narosa publication House, New Delhi, 1997.
2. Azer S.A., Mc Caughan G.M. and Stacey N.H., Liver and Environmental Xenobiotics, Narosa Publishing House, New Delhi, 1997, 178.
3. Brattin W.J., Glende E.A. and Recknagel R.O., Pathological mechanism in carbon tetrachloride hepatotoxicity, J. Free Radic. Biol. Med., 1985, 1, 27–38.
4. Comporti M., Lipid peroxidation and cellular damage in toxic liver injury, Lab. Invest., 1985, 53, 599–623.
5. Abdel-Rahman M.K. and Abd El-Megeid A.A., Hepatoprotective effect of soapworts (*Saponaria officinalis*), pomegranate peel (*Punica granatum* L) and cloves (*Syzygium aromaticum linn*) on mice with CCl_4 hepatic intoxication, World J. Chem., 2006, 1, 41–46.
6. Recknagel R.O., Carbon tetrachloride hepatotoxicity: status quo and future prospects, Trends Pharmacol. Sci., 1983, 4, 129–131.
7. Slater T.F., Free-radical mechanism in tissue injury, Biochem. J., 1984, 222, 1–15.
8. McCay P.B., Lai E.K., Poyer J.L., DuBose C.M. and Janzen E.G., Oxygen- and carbon-centered free radical formation during CCl_4 metabolism: observation of lipid radicals *in vivo* and *in vitro*, J. Biol. Chem., 1984, 259, 2135–2143.
9. Sultana S., Ahmad S., Khan N. and Jahangir T., Effect of *Emblica officinalis* (Gaertn) on CCl_4 induced hepatic toxicity and DNA synthesis in Wistar rats, Indian J. Exp. Biol., 2005, 43, 430–436.
10. Decker T., Lohmann-Matthes M.L., Karck U., Peters T. and Decker K., Comparative study of cytotoxity, tumor necrosis factor and prostaglandin release after stimulation of rat kupffer cells, murine kupffer cells, and murine inflammatory liver macrophages, J. Leukocyte Biol., 1989, 45: 139–146.
11. Edwards M.J., Keller B.J., Kauffman F.C. and Thurman R.G., The involvement of kupffer cells

in carbon tetrachloride toxicity, Toxicol. Appl. Pharmacol., 1993, 119, 275–279.

12. Pradeep K., Mohan C.V.R., Anand K.G. and Karthikeyan S, Effect of pretreatment of *Cassia fistula* Linn. leaf extract against subacute CCl4 induced hepatotoxicity in rats, Indian J. Exp. Biol., 2005, 43, 526–530.
13. Chattopadhyay R.R., Possible mechanism of hepatoprotective activity of *Azadirachta indica* leaf extract, Part II, J. Ethnopharmacol., 2003, 89, 217–219.
14. Chatterjee T.K., Medicinal Plants with Hepatoprotective Properties in Herbal Opinions, vol. III., Books and Allied (P) Ltd, Calcutta, 2000, 135.
15. Jong S.C. and Birmingham J.M., Edible mushrooms in biotechnology. Proc. Asian Mycol. Symp., Seoul, Korea, 1992, 18.
16. Acharya K., Medicinal properties of mushroom. In: Acharya S.N. and Thomas J.E. (Eds) Advances in Medicinal Plant Research, Research Signpost, Kerala, India, 2007, 215–236.
17. Acharya K., Samui K., Rai M., Dutta B.B. and Acharya R., Antioxidant and nitric oxide synthase activation properties of *Auricularia auricula*, Indian J. Exp. Biol., 2004, 42, 538–540.
18. Acharya K., Yonzone P., Rai M. and Acharya R., Antioxidant and nitric oxide synthase activation properties of *Ganoderma applanatum*, Indian J. Exp. Biol., 2005, 43, 926–929.
19. Pal J., Ganguly S., Tahsin K.S. and Acharya K. *In vitro* free radical scavenging activity of edible wild mushroom *Pleurotus squarrosulus* (Mont.) Singer, Indian J. Exp. Biol., 2010, 47, 1210-1218.
20. Biswas G., Sarkar S. and Acharya K., Free radical scavenging and anti-inflammatory activities of the extracts of *Astraeus hygrometricus* (Pers.) Morg, Lat. Am. J. Pharm., 2010, 29, 549–553.
21. Reitman S. and Frankel A.S., A colorimetric method for the determination of serum glutamic oxaloacetic and glutamic pyruvic transaminases, Am. J. Clin. Pathol., 1957, 28, 56–63.
22. Jendrassik L. and Grof P., Vereinfachte photometrische Methode zur Beshmung des Bilirubins, Biochem. Z., 1938, 297, 81–89.
23. Kind P.R.N. and King E.J., Estimation of plasma phosphatase by determination of hydrolyzed phenol with antipyrene, J. Clin. Pathol., 1954, 7, 322–326.
24. Mc Cord J.M. and Fridovich I., Superoxide dismutase, an enzymatic function for erythrocuprein, J. Biol. Chem., 1969, 244, 6049–6055.
25. Beers R.F and Sizer I.W., A spectrophotometric method for measuring the breakdown of hydrogen peroxide by catalase, J. Biol. Chem., 1952, 195, 133–140.
26. Yagi K. and Rastogi R., Assay for lipid peroxides in animal tissues by thiobarbituric acid reaction, Anal. Biochem., 1979, 95, 351–358.
27. Ellmann G.L., Tissue sulfhdyrl group, Arch. Biochem. Biophy., 1959, 82, 70–72.
28. Lowry H.D., Rosenberg N.J., Farr A.L. and Randa R.J., Protein measurement with Folin phenol reagent, J. Biol. Chem., 1951, 193, 265–275.
29. Kaplowitz N., Aw T.Y., Simon F.R. and Stolz A., Drug-induced hepatotoxicity, Ann. Intern. Med., 1986, 104, 826–839.
30. Plaa G.L. and Hewitt W.R., Detection and evaluation of chemical induced liver injury. In: Hayes A.W. (Ed) Principles and Methods of Toxicology, Raven Press, New York, 1982, 407–440.
31. Plaa G.L. and Hewitt W.R., Quantative evaluation of indices of hepatotoxicity. In: Hayes A.W. (Ed) Toxicology of the Liver, Raven Press, New York, 1982, 103–120.
32. Sallie R., Tredger J.M. and William R., Drugs and the liver, Biopharmaceut. Drug Dispos., 1991, 12, 251–259.
33. James G.W.L. and Pickering R.W., The protective effect of a novel compound RU-18492 on galactosamine induced hepatoxicity in rats, Drug Res., 1976, 26, 2197–2199.
34. Biswas G., Sarkar S. and Acharya K., Hepatoprotective activity of the ethanolic extract of *Astraeus hygrometricus* (Pers.) Morg, Dig. J. Nanomater. Bios., 2011, 6, 637–641.
35. Thawbrew M.I., Joice P.D.T.M. and Rajatissa W.A., Comparative study of efficacy of *Paetta indica* and *Osbeckia octandra* in the treatment of liver dysfunction, Planta Med., 1987, 53, 239–241.
36. Plaa G.L. and Hewitt W.R., Principle and Methodology of Toxicology, vol. II, Raven Press, New York, 1989, 399.
37. ElSisi A.E., Earnest D.L. and Sipes I.G., Vitamin A potentiation of carbon tetrachloride hepatotoxicity: role of liver macrophages and

active oxygen species, Toxicol. Appl. Pharmacol., 1993, 119, 295–301.

38. Smith S.M., Grishsm M.B., Nancy E.A., Granger D.A. and Kvietys P.R., Gastric mucosal injury in rat. Role of iron and xanthine oxidase, Gastroenterol., 1987, 92, 950–956.
39. Halliwell B. and Gutteridge J.M.C., Free Radicals in Biology and Medicine, Clarendon Press, Oxford, 1989, 416.
40. Zimmerman H.J. and Seef L.B., Enzymes in hepatic disease. In: Goodley E.L. (Ed) Diagonistic Enzymology, Lea and Febiger, Philadelphia, 1970, 1-38.
41. Recknagel R.O., Glende Jr., E.A. and Britton R.S., Free radical damage and lipid peroxidation. In: Meeks R.G. (Ed) Hepatotoxicology, CRC Press, Boca Raton, FL, 1991, 401-436.

*****